

---

## **TEETH ROOT GRANULOMA AS FOCAL DISTURBANCES OR PERTURBATIVE FIELDS. WHAT TOOTH IS DISTURBING ON WHAT ACUPUNCTURE POINT AND WHICH TEETH ROOTS CAUSE WHAT DISEASE (EQUINE AND CANINE)**

Dr. med. vet. Uwe Petermann (DVM)  
Veterinary Acupuncture Clinic  
Melle, Germany

### **Abstract**

The term “focal disturbance” or “perturbative field” is going back to the German doctor Ferdinand Huneke, who developed in 1925 a treatment concept called “Neural therapy”. He figured out that every chronic disease can be caused by such focal disturbances. The most powerful disturbances are caused by teeth root granuloma. Local laser treatment with a 90w 904nm impulse laser is known as valid treatment method of these teeth root granuloma.

The connections between each tooth and the corresponding body acupuncture point are demonstrated by clearly defined teeth maps. The treatment concept is explained by some special case studies with chronic heart disease, COPD/RAO and Cushing disease.

### **Introduction**

In this lecture I will talk about especially the disturbing foci at the teeth roots and how they can cause chronic disease. It will be pointed out what connections between a special tooth and kinds of illnesses I have found over the last 25 years and that each tooth is disturbing on one concrete acupuncture point.

The use of topical LLLT in combination with acupuncture points are described here as being a highly effective possibility to cure the teeth roots by demarcation of the root abscesses or root granuloma. Treatment of the teeth root problems opens the way to stop the chain effects from that many chronic, degenerative and chronic allergic diseases derives from.

### **Which types of illnesses arise from focal disturbances in the teeth?**

Generally one can say every kind of chronic disease can be caused by such a teeth focus, but there are some diseases which are always caused by a teeth root focus in a special tooth and sometimes in a special group of teeth. From my experience of thousands of cases in horses and dogs where teeth root foci were involved, I can confirm the following relationships between a special tooth and a certain disease very clearly. Spondylosis in dogs and chronic back problems in horses are mostly caused by a focus in the 1st molar tooth (M1) in the upper jaw. This tooth is even responsible for all chronic degenerative joint diseases. Hip dysplasia in dogs and iliosacral joint disease in horses are caused beside M1 by the canine tooth in the upper jaw. Osteochondrosis dissecans, narvicular disease and many other arthrosis in the front legs are caused by the 3<sup>rd</sup> premolar tooth in the upper jaw, beside M1. In nearly 500 cases of chronic obstructive bronchitis, COPD/RAO I found the 2<sup>nd</sup> molar tooth in the upper jaw. Every kind of heart disease can be caused by a focus in the 3<sup>rd</sup> premolar tooth in the upper jaw. In nearly 100 horses with moon blindness I found the 4<sup>th</sup> premolar (P4) in the upper jaw. In about 20 horses with Cushing disease, I found always two teeth: P4 and M1.

**Disturbing foci in the teeth are difficult to find**

The problem is, that these foci normally are not to find by conventional diagnosis. By radiographics we can only find some cases of teeth root inflammations and apparent sinusitis. But most of the teeth foci are not seen in radiographics, because the granulomas are too small. These granulomas are only seen in pathological sections post mortem. Therefore the only way to diagnose these foci is RAC control. There are two laser frequencies which react on these foci and therefore the body develops a change in the heart beat one can feel by RAC check. One is fr. 7 according to Bahr which shows us so called "hidden" disturbing foci and the other is fr. A" according to Nogier.

**Teeth foci are the troublemaker Nr.1**

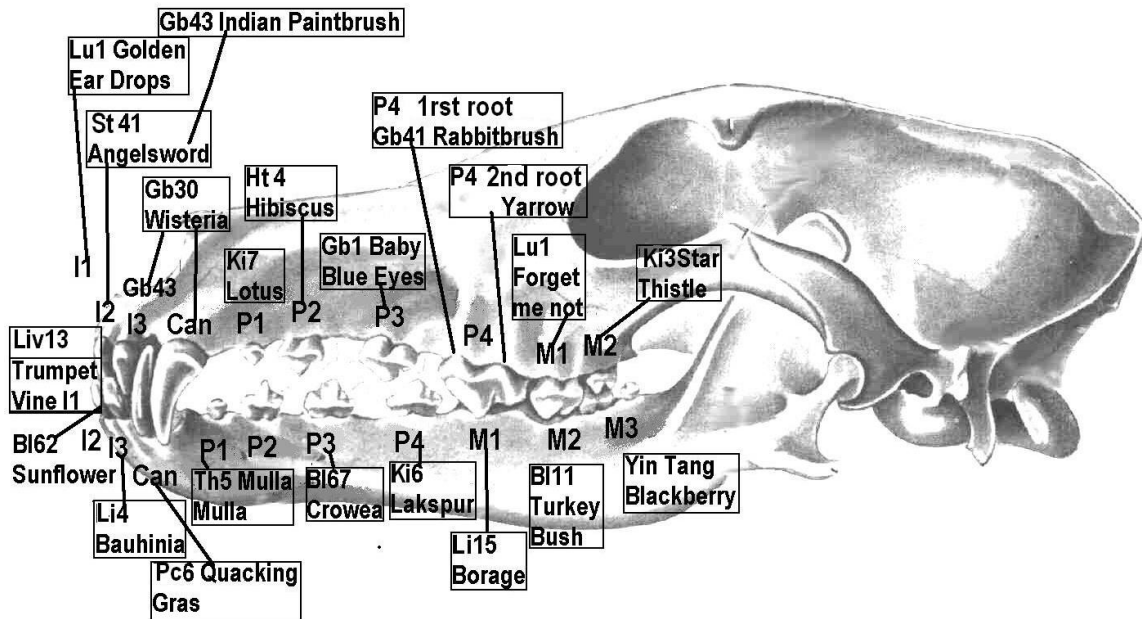
One reason for that teeth root problems make even stronger problems than scar foci at the body may be that teeth have a very direct nerve connection by the brain nerves to the central nerve system. The closer the nerve connection is from a focus to the brain, the stronger is the disturbance. The second reason is that they are disturbing on special acupuncture points, which are imbalanced all the time by this disturbance.

**Teeth correlations to acupuncture points**

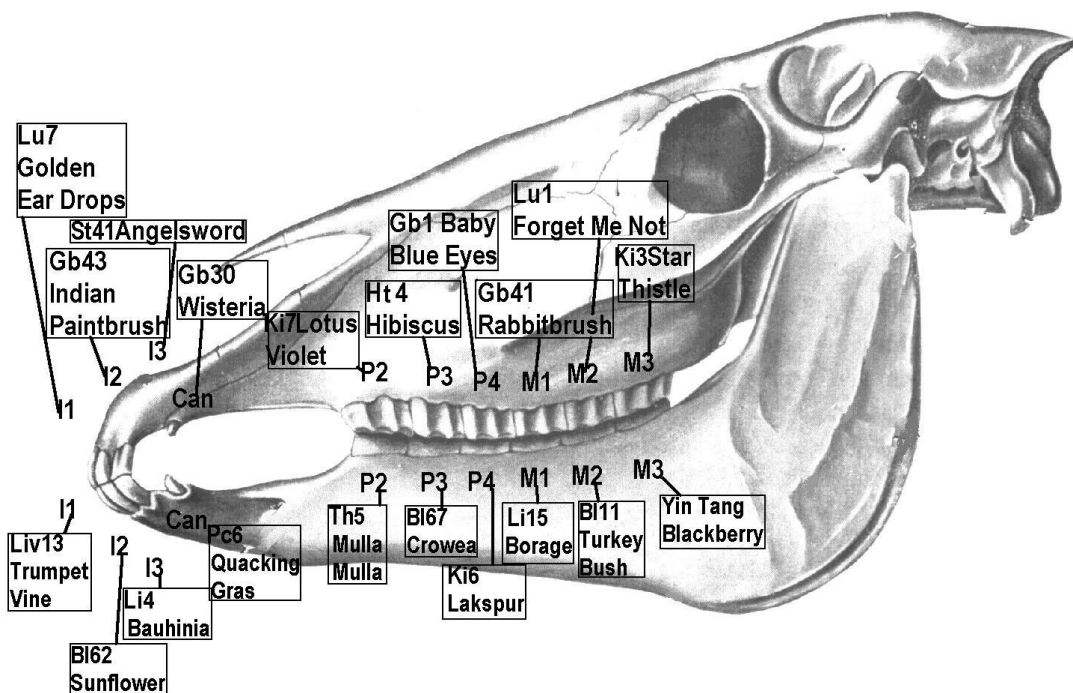
Some years ago in human medicine German Academy of Acupuncture (DAA) started to look for special connections from each tooth to acupuncture points. About 10 years ago I followed this idea and tried to do the same in horses and dogs. I could find some very interesting correlations. E.g., I found the 2<sup>nd</sup> molar tooth in the upper jaw disturbing LU 1, the Mu point or Alarm point of the Lung. This tooth in the upper jaw was that tooth that I already found before in nearly every COPD horse as a disturbing focus. The 4<sup>th</sup> premolar tooth in the upper jaw disturbs the point Gb1, the Eye Point in Ear Acupuncture. This tooth I already found in every case of Moon blindness (Periodic Eye Inflammation) in horses.

**Correlation between teeth, acupuncture points and flower essences**

Another interesting aspect is the connection of these acupuncture points to Flower essences. Therefore the DAA looked for Flower Essences, like Californian Flower Essences, Bach flowers, Australian Living Essences and Australian Bush Essences, that support the acupuncture points which are disturbed by the teeth. The idea behind this was, to support the disturbed acupuncture point and perhaps even support the teeth to solve the problem in its root. And indeed, what was found was working great! The Flower Essences really help a lot to heal the disturbing foci at the teeth. The following pictures (picture 1 and 2) show the teeth with the points on which they disturb and the related Flower Essence that supports the acupuncture and LLLT to eliminate the teeth foci. For treatment with the Flower Essences one gives one drop in dogs and to two drops in horses from the Stock Bottle a day. Or one can make a dilution of the Flower Essences by giving 10 drops of the remedy into 30ml of water and give three times 10 drops a day from the dilution in dogs and three times 20 drops in horses.



Picture 1, Teeth related acupuncture points and related Flower Remedies in dogs. I1-I3 means 1st to 3rd Incisivus, P1-4 means Premolar Teeth M1-3 means Molar Teeth



Picture 2, Teeth, related acupuncture points and related Flower Remedies in horses I1-I3 means 1st to 3rd Incisive, P1-4 means Premolar Teeth M1-3 means Molar Teeth

## **Treatment of the Disturbing Focus with Low Level Laser Therapy (LLLT) and acupuncture**

The use of LLLT has proven itself to be an effective therapy in healing wounds and as a local anti-inflammatory therapy. LLLT has the capability in activating the demarcation of abscesses and even in the disturbing focus granuloma. For this we need a 904nm impulse laser with impulse peak power of 50-90 watt with an impulse width of 200nsec. This kind of laser has the big advantage that it provides strong light flashes which can penetrate deeply into the tissue and we have enough laser energy in the depth of tissue where it is needed.

Because of the very duration of the flash, only 200nsec even with the strong power of 90 watt the laser doesn't warm or heat up tissue. The optimum anti-inflammatory impulse frequency is the frequency A', 292Hz according to Nogier. This is the frequency we use for disturbing focus treatment at all, in scars and teeth. Even stronger, exactly 128 times stronger, works the new frequency A'', 37376Hz. By activating the demarcation of the granuloma in the disturbing focus it is possible for the organism to heal these processes and eliminate the disturbance. Four to eight laser sessions with the above mentioned impulse lasers are necessary. The length of the treatment or session varies according to the depth of the process within the soft tissue ranging from 30 to 60 seconds. In some cases in horses it may require treatment time (see case study No. 2). In such cases impulse lasers with 90 watt impulse peak power are necessary to reach the focus and activate demarcation. For disturbing focus treatment in any case we use two opening points to support tissue demarcation, TH5 and Gb41.

### **“Hidden” disturbing foci in the teeth**

Beside those teeth acting on fr. A' or A'' like in scars we have teeth disturbing foci which do not act on this frequency. That will mean we cannot check and find it by RAC control and even cannot treat it with this frequency. For a long time one could not discover these foci. For that reason they were called “hidden” disturbing foci. About 10 years ago Bahr figured out that these foci react on frequency “7” according to Bahr (299,5Hz). With fr. 7 it is the same like fr. A' and A''. In modern impulse laser we find fr. 7' (38368Hz) which again is 128 times stronger because it has 128 time more beats/sec. To find and treat these so-called “hidden” disturbing foci we use fr. 7' according to Bahr. For “hidden” disturbing focus treatment in any case we use beside the two opening points, 3H 5 and GB 41, KID 7 and KID 3.

With disturbing focus treatment I have personal experience in thousands of patients, and it is still always amazing to see while using this treatment especially even chronic pain very often disappears at once and severe diseases like Cushing disease, RAO or MRSA infections can heal within a short time.

## **Cases that demonstrate diseases caused by the perturbative field principle**

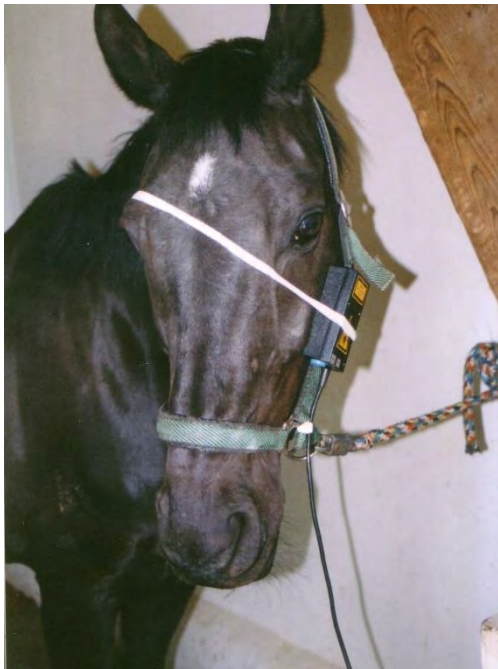### **Case study Nr. 1**

A ten-year old Trakehner gelding with very severe COPD, was brought to acupuncture treatment after years of conventional treatment (hyper infusion, Dexametason, Clenbuterol, Bromhexin, inhalation ultra sound fogged salt water). The horse had not been able to work for the previous six months, despite permanent therapy before acupuncture. A hyper infusion therapy had been carried out three weeks previously (4 days, daily administration of 40 liter phys. NaCl solution intravenously within 3 hours). Also up to the day of the first acupuncture, the animal had inhaled cortisone daily. In addition, the horse had got daily doses of beta mimetic and secretolytic drugs (clenbuterol, acetylcystein, bromhexin). The findings of the examination were as follows: violent dyspnoea at rest, breathing: 36/min., intensely

costal breathing with abdominal compression. In auscultation we heard extreme droning and rattling noises over the area of the main bronchi and trachea at rest. In percussion, we found an extended lung percussion area the width of more than a hand with unusually loud resonance. Bronchoscopic examination showed large quantities of highly viscous secretion in the trachea and in the main bronchi with swelling of the bifurcation trachea. The body temperature was normal, and there were no clinical signs of a sinusitis.

The acupuncture treatment took place at 2 -3 day intervals and on the points LU 7, KI 3, ST 40, BL 14, BL 17, BL 23, CV 17, LI 13 and TH 5. The acupuncture examination detected a disturbing focus in the stomach meridian, in the area of the point ST 1-1, and pollution with mercury. The point ST 1-1 lies at the root of the second molar tooth in the maxilla or at the sinus maxillaris over this tooth.

The second molar of the upper jaw is known, to disturb directly at the point LU 1, the Muo point of the Lung meridian. The sinus maxillaris and the located point on the first maxillary tooth were treated using a laser area probe (8 x 10Watts impulse- diodes) for two minutes (picture 3).



Picture 3, Horse with 8x 10 watt impulse laser shower at the molar teeth. The laser probe is fixed with a bandage at the halter and head.

Within 10 minutes following the end of the irradiation, a recognisable deepening of the breathing could be ascertained. The breathing frequency decreased to 28 breaths per minute, the droning noise had become quieter but the secretion rattling noise had become louder because there was a lot of secretion mobilised by the treatment. But the patient's state improved only slightly in the following days of treatment. In spite of that, the owner was quite satisfied with the success. Because I was not content by the further improvement, for me it seemed sensible to break off the therapy. However, the owner insisted on further treatment and so we carried on. Because for me the clinically unapparent sinusitis, in the area of the left upper second molar tooth, had a key function in the therapy of this patient, I decided to extend the time of treatment with the laser-douche (LLLT, means Low Level Laser Therapy) for this area from 2 to 10 minutes. No distinct change in breathing could be determined during the acupuncture treatment and the first three minutes LLLT of the sinusitis area which followed. But then, from the 4th to the 5th minute, the depth of the breathing suddenly increased vehemently and

reached a state similar to that following an injection of breathing stimulants. The breathing became normal again about 5 minutes after the treatment was discontinued. On the following morning, the horse gave the impression of being free of symptoms for the first time. The breathing rate was around 8 breathings per minute (20-24 at all the days before the extended LLLT of the sinus maxillaris). Breathing was absolutely normal, no droning or rattling sounds could be heard following breathing stimulation with 10 ml Lobelin® (Lobelinhydrochlorid). The breathing got worse each time between treatments, at first 20 per minute in resting, then 16 and finally 8 to 12 per minute after further twelve treatments in the

same way. A large increase in the depth of the breathing was to be observed during the sinus treatment in the first ten succeeding treatments, although it was weaker from time to time. Even in this case, when an extraordinary large number of treatments had to be made, the effort was still justified as the horse had neither clinical nor bronchoscopic signs of illness at the end of the treatment and up to today, after a three-year period of observation, the horse has worked, been in very good condition and has returned to professional tournament sport (S-dressage). For me this patient was one of the most convincing cases in my life, showing the direct influence of disturbing focus in failure of immune regulation leading to allergy.

### **Case study Nr. 2**

A 20 year-old horse, a Knappstrupper Stallion, has had Moon blindness for more than 7 years. Two years ago he had a vitrektomie operation at Munich Veterinary University on both eyes. This clinic is specialized in this kind of operation. But the disease did not stop after several acute breakouts, sometimes on the left, sometimes on the right and at last on both eyes at the same time worsened the problem so severe that the horse should be put down. Instead of that, the horse came for laser acupuncture in the acute state on both eyes. At that moment the horse got antibiotics and dexamethasone local and parenteral. The whole medication was stopped in the moment of the first acupuncture treatment. I found on both sides the first molar tooth of the upper jaw as the causing disturbing focus. The first molar tooth in the maxilla is known to disturb the eye point of ear acupuncture that is identical with the body acupuncture point GB 1. Both teeth and the sinus above were treated with a 90 watt impulse laser with frequency 7 for five minutes each. The points around the eye, GB 1, TH 23, BL 1 and ST 1 were treated with laser frequency A' each for one minute. The according pair of opening points GB 41, (master point against rheumatism and Prostaglandin point of ear acupuncture and its partner TH 5, the Thymus point of ear acupuncture) as well as KI 3 the source point of Kidney were treated with fr.5 for 20sec each. KI 3 was chosen because Kidney generally is responsible for the teeth and one can rise the Yin of the Kidney by KI 3. To support the eye point, GB 1, and the teeth disturbing foci on the first molar teeth I gave one drop a day of the Californian flower essence Baby Blue Eyes for three weeks.

Immediately after the first treatment the horse seemed to feel more comfortable and to have less pain. It started to eat and held its eyes more opened. The next day the signs of acute inflammation had decreased evidentially. After 4 days with daily treatment in the same way there were no more signs of inflammation at all. After 10 days of treatment the horse was sent home to its owner that carried on the treatment for 4 more weeks. After that the horse has had no further Moon blindness attacks till now for 3 months.

### **Case study Nr. 3**

A 27 year-old Friesian gelding with extreme severity of the ECS was presented for acupuncture treatment after 3 years of Pergolite® treatment. The horse was emaciated, the skin in several areas was hyperkeratotic, the coat long and shaggy or almost hairless (see Figure 4). The back showed severe lordosis. The horse was completely lethargic. Another main complaint was a severe bloody purulent sinusitis of the left side of the nose. Large amounts of bloody purulent, foul-smelling secretion ran from the left nostril. This disorder



Picture 4 - 27 year-old Friesian gelding with extreme severity of the ECS before laser acupuncture

had previously been treated for more than 1 year with different antibiotic cocktails. The patient was examined with the techniques of Pulse Controlled Laser Acupuncture Concept (PCLAC) or the RAC controlled acupuncture. How profound and complex this disease was, was discovered acupuncture diagnosis. In addition to the kidney, the adrenal gland, the liver, the pancreas and, in particular, the master control system, the pituitary gland were involved in the overall disease. The triggering basic problem was the destructive inflammation of the 4th premolar (P4, disturbs on acupuncture point

GB 1) and the first molar (M1, interferes with GB 41) in the left upper jaw of the horse. P4 was hidden focal disturbance, M1 is a normal focal disturbance. Based on these teeth also purulent sinusitis had developed in the horse. Even worst for the ECS was the fact, that the same teeth also on the right side of the jaw had disturbance foci. This cluster of disturbance foci, reveals itself in identical form in all horses with ECS and also in dogs with Cushing's syndrome. The treatment was as follows: The horse was hospitalized and treated 5 times weekly for 14 days.

The previous medication was discontinued immediately. Acupuncture was carried out with a 90W pulse laser for 20 sec per point: KID 7 (treatment with frequency Bahr 1) LIV 8 and SP 2 (Bahr 2), KID 3 as an anti-oscillatory point (Bahr 5), SP 4 (Reininger SP), LIV 3/13 (Reininger Liv), TH 5 (Reininger TH). TH 5 and SP 4 are both Luo points and cardinal points. In this combination, the points are combined as Luo points after noon-midnight rule. These two points have been proven as master points against inflammation in combination with local laser therapy of the diseased organ or infected wound (Fr. A"). This protocol has proven in my practice as the optimal treatment for all kinds of acute and chronic infections, including MRSA infections. There are basically no drugs, not even antibiotics administered. Besides these two points local laser therapy of dental foci, such as purulent sinusitis with the pulse laser (Fr. A" 37376Hz) was essential. The hidden disturbing focus was treated with Fr 7 (38368Hz).

In addition to the local inflammatory therapy of the teeth and the sinusitis, the thyroid in addition to their acupuncture points TH 6 and LIV 13 (1 min A" and TH mixed) and the pituitary gland (1 min fr. and LIV mixed) were treated locally with the laser.

Laser acupuncture treatment was carried out three weeks 5 times a week in my clinic.

Thereafter, the same treatment was continued for 8 weeks at home by the owner. Then the horse had completely recovered. Teeth and sinusitis were cured, skin was back to normal, the coat was short and glossy, the muscles had gained on healthy amount, so that the back showed no more lordosis (picture 5) and the horse could be ridden again despite its advanced age.



**Picture 5 - Same horse 10 weeks later after laser acupuncture**

### **Discussion**

I have seen thousands of cases that clearly show the teeth disturbing focus principle. These three examples out of those show a direct connection between disturbing focus in the teeth and the disease arising from it and on the other hand how laser therapy of the disturbing focus in combination with acupuncture can treat the disease from its roots. The results show that acupuncture as a regulating autonomous nervous system therapy, in connection with laser treatment of the disturbing focus, is extremely suitable to treat irregularities.



---

**Literature list**

1. Bergsmann, O. (1977) : Die biokybernetische Wirkung der Akupunktur im klinischen Versuch. Dtsch. Ztschr. f. Akup. 5, 131ff
2. Bergsmann, O. (1980) : Pathogenetische Aktivität der Störfelder. Der informierte Arzt 20, 41-48
3. Karu, T. et al. (1993) Suppression of human blood chemiluminescence by diode laser irradiation. Laser Therapy 5, 103-109
4. Kellner, G. (1963) : Wirkung des Herdes auf die Labilität des humoralen Systems Öst.Z. Stomatol. 60, 312
5. Kellner, G. (1965): Nachweismethoden der Herderkrankungen und ihre Grundlagen. Therapiewoche 15, 1267-1274
6. Kellner, G. (1965): Zur Histochemie der Narbe. Hippokrates 36, 777-785.
7. Kellner, G. (1979) : Der Herd in experimentell-histologischer Sicht. Österr.Ärztztg. 34, 933-935
8. Kluger, L. (1991) : Odontogene Störfeldmöglichkeiten. In: Österr. Med. Ges. f. Neuraltherapie - Regulationsforschung (Hrsg.): Herd-Störfeldgeschehen. Facultas, Wien 40-46
9. Oshiro, T., Maeda, T. (1993) Application of 830nm Diode Laser LLLT as Successful Adjunktive Therapy of Hypertrophoc Scars and Keloids. Laser Therapy 1993 155-166
10. Congress 2000, Vienna, 144-148
11. Pischinger, A.: Das System der Grundregulation. Haug, Heidelberg 1990
12. Rösti, A. (2000) Look and Key of Chronic Diseases. Proceedings of IVAS World Congress 2000, Vienna, 130-135
13. Schoeler, H. (1965) Zur elektrischen Untersuchung von Narben. In Groß, D.: Therapie über das Nervensystem, Band 2, 48. Hippokrates Verlag, Stuttgart
14. Stacher, A. (1965) Die Therapie der Herderkrankungen. Therap.woche, 15, 1278-1284.
15. Stacher, A. (1966) Zur Wirkung der Herde auf den Gesamtorganismus. Österr. Zeitschr. Stomat. 63, 294-303.
16. Strittmatter, B. (1998) Das Störfeld in Diagnostik und Therapie.
17. Strittmatter B. (1997) Verborgene Zahnstörfelder - häufiger Grund für "unerklärliche" Therapieresistenz in der Akupunktur, Der Akupunkturarzt, Aurikulothérapeut 1/97 und 2/97)
18. Tucker, D. (1990) Laser and Electrodiagnostic Techniques for the Isolation and Treatment of Odontogenous Foci American Journal of Acupuncture, Vol 18, No.4,
19. Zilk, A. (1997) Persönliche Mitteilung