

Equine and Canine Ear Acupuncture / Equine and Canine Laser Acupuncture

Dr. Uwe Petermann, DVM
Melle Germany

- Equine and Canine Ear acupuncture, easy entry to acupuncture by western thinking
- Equine and Canine Laser acupuncture, a symbiosis of acupuncture and low level laser therapy
- Lecturing time 5h

Summary

The *Pulse Controlled Laser Acupuncture Concept (PCLAC)* is a modern form of therapy, where traditional acupuncture is combined with *Low Level Laser Therapy (LLLT)*, Ear Acupuncture and RAC Pulse Control to use the synergic effects of these therapies. Beside stimulation of acupuncture points the laser light also can be used for the therapeutic impact of LLLT in tissue. A huge range of acute and chronic disease can be treated very effectively. By use of vegetative reflexes, so called RAC or Nogier- reflexes, which emerge from stimulation of *active* (imbalanced) acupuncture points, has been developed a very sensitive diagnostic system, especially if we use Ear Acupuncture where we find the reflex points of the complete body including all meridian points in the small area of the ear. This is a really holistic diagnostic system which shows us (nearly) all backgrounds in the body that lead to chronic disease. All active or imbalanced points the patient shows to us are in the same way important treatment points because the strength of the RAC reaction is a measurement of the strength how the point balances the Qi in the patient.

Introduction

After acupuncture in human medicine has developed itself from outsider medicine to a recognized high effective therapy we can recognize acupuncture in veterinary medicine in the same way. As hardly any other treatment acupuncture seems not only to treat symptoms rather it always tries to find the root of the disease and use it as a central element of its treatment. Only through this really causal treatment the impressive successful outcome in so many previously not treatable diseases is to explain.

Controlled acupuncture is a further development of traditional acupuncture and far more than just the treatment of points with a mild laser light instead of needles. This medicine is a synthesis of two each for its own very effective therapies: acupuncture and LLLT (Low Level Laser Therapy) that means local laser treatment of diseased tissue.

In addition a vegetative Reflex in the patient helps the therapist with the choice of the points to be treated. This reflex gives information on whether the point gives a strong therapeutic response. Controlled acupuncture in this way can also be used as an excellent diagnostic tool.

To go at the root of the disease and not just dealing with a symptom is the particular concern of controlled acupuncture. Thus especially for chronic illnesses, it is essential to uncover underlying causes. For this just ear acupuncture is very useful, because the ear provides us with a small-scale representation of the physical discomfort of the patient and makes acupuncture diagnostics so much easier. We only have to scan this small area of the ear which represents the whole in an extremely detailed matter. All the relevant points are lying close to each other and are thus easily to check in a few seconds. The active ear points found by RAC control give us both possibilities as well in orthopedics (lameness), as well as in internal disorders: diagnostic *and* treatment. This kind of diagnostic gives us a far-reaching assessment of all thinkable disorders in the body. Very often I am absolutely surprised what I find, but in the same moment I wonder why I didn't see this connection between symptoms and the underlying illness before acupuncture diagnostic. The outcome is always logic and understandable.

PCLAC rests on four pillars

The main pillar is traditional acupuncture

The **main pillar** clearly is traditional veterinary acupuncture, based in a 3000 years old tradition and experience since Sunjang who was the father of veterinary acupuncture. This is not the main issue of this lecture but some aspects should be mentioned here.

Here the function circles or meridians play a fundamental role. They are responsible for a smooth transport of Qi, the individual force of life. A modern part of this life force is ATP, which is produced in the citric acid circle within the Mitochondria of the body cells. Here the aerobic respiration takes place and produces ATP that provides the body with energy for all life processes from synthesis of enzymes to the relaxation of muscles, which means for all energy consuming processes in the body.

In any disease of the organism we have a disturbance of the optimum flow of the Qi, what has the consequence, that the balance in the traditional sense between Yin and Yang, in the medical sense between parasympathic and sympathetic nervous system, is disturbed. An example may clarify this.

In case of a blockage in the upper thoracic spinal column we have an irritation of the roots of the efferent nerves. This leads to a contraction of the back muscles and also simultaneously the blood vessels in the concerning body segment. On one hand, this contracture of the muscles solidifies the resulting blockage. On the other hand the contraction of the muscles results in a poor blood perfusion. This simultaneously is strengthened by a contraction of the blood vessels in this segment by the same process arising from the irritated nerve. The supply of oxygen and nutrients is reduced. The provision with ATP, what the muscle cells need for relaxation, stagnates. The muscles indurate more and more and a vicious circle of clamping and occlusive disease has its beginning. The production of ATP and so flow of Qi is disturbed. We have Qi Stagnation.

In addition, if this affected segment possibly is responsible for the vegetative control of cardiac function, the growing irritation of the nerve root will influence vegetative regulation of the heart. The result is autonomic disorders of cardiac function with under certain circumstances life-threatening consequences.

At this point it should be noted that in my experience in many horses and dogs which suffer from heart disease a significant proportion in similar incidents is based in such failures of vegetative control. This mutual influencing of organ function and back pain in a segment is obviously not only for the heart problems but also for all other organ- and many, especially chronic orthopedic disease.

The second pillar of controlled acupuncture is ear acupuncture

A second pillar of controlled acupuncture is ear acupuncture. An important aspect of ear acupuncture is its ease clarity for western trained physicians, since this kind of acupuncture originates in western thinking. Its inventor, the French acupuncturist Dr. Paul Nogier empirically found out that the ear reflex points have a direct impact on diseased structures of the spinal column and the whole limbs. These new points on the ear at that time had not any connection with traditional acupuncture points. When he stated to pierce these points, as usual in *traditional acupuncture*, with needles, *ear acupuncture* was born. In the course of his following work and experience he established a complete image of the whole body on the ear, at first for the orthopedic points, thus spinal column and joints and the accompanying muscles and tendons, and even subsequently for organs. These points follow its sphere of influence, named: *knee point, elbow point, hip point, point of 2. neck vertebra*, but also *lung point vegetative heart point, kidneys point*, etc.




Figure 1, Dr. Nogier at his desk, in 1950

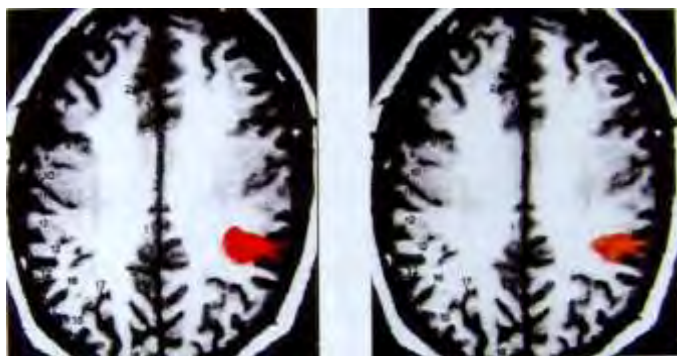


Figure 2, Alimi 2003
FMRI from Pain provocation in the thumb and acupuncture stimulation of the ear point of the right thumb.

The neurological connections of ear points with the central nervous system and the periphery can now be shown by FMRI. In continuation of Nogier's idea ear acupuncture was explored and developed further in the German Academy for Acupuncture (DAA) under the leadership of Prof. Bahr.

There were found points for nerves, ganglia, the spinal cord, endocrine and exocrine glands and various parts of the brain. Also points with superordinated influences were found: Endorphin point, Histamine point, Prostaglandin point, β -adrenergic point, ACTH point etc., just to mention some of those.

In the last twenty-five years I have, more or less in lockstep with human medicine, found almost all of these localizations also at the ear of dogs and horses with clear determinations and could summarize these points to ear maps. Figure 3 shows my first equine ear map from 1989. All these points can be combined for modern medical aspects for therapeutic purposes with outstanding therapeutic success.

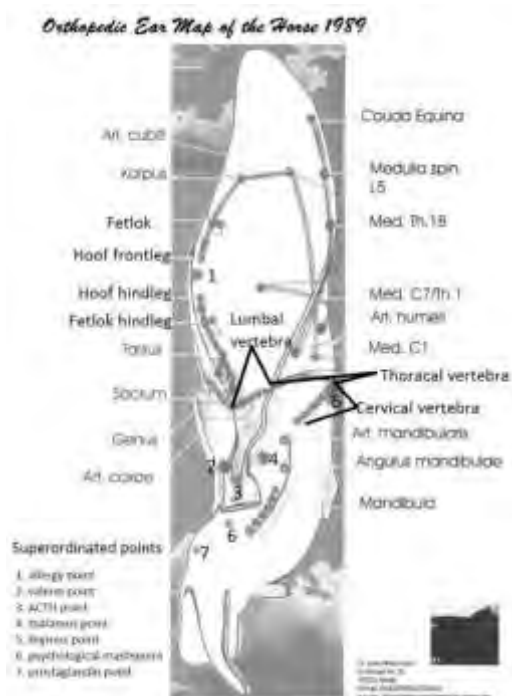


Figure 3: Skeletal structures identified by the author and an auricular map of these created in 1989. Points 1-7 on the auricular map have been found to have special effects and are superordinated points in ear acupuncture (Reprinted with permission from Petermann U. Pulse Controlled Laser Acupuncture Concept (PCLAC). 2007: www.akupunkturtierarzt.de)

If ear acupuncture is combined with RAC controlled acupuncture, the finding of the active points open the patient's medical history with (almost) all its causal relationships to the investigator.

In orthopedic diseases “controlled acupuncture” can be used as a thorough lameness diagnostic I compared the outcome of ear lameness diagnostic for more than 10 years with classical examination and nerve block anesthesia and had such a good relationship with both outcomes that in the last 15 years I disclaim nerve block anesthesia to save time. The same is true for diagnostic of internal disorders.

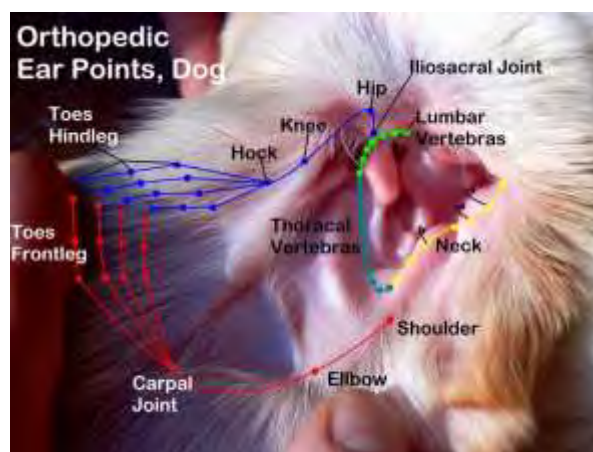


Figure.4, orthopedic ear Map of the Dog (Reprinted with permission from: Petermann U. Kontrollierte Laserakupunktur bei Hund und Pferd. Sonntag Verlag in MVS Medizinverlag. Stuttgart, Germany: Thieme Verlagsgruppe 2011)

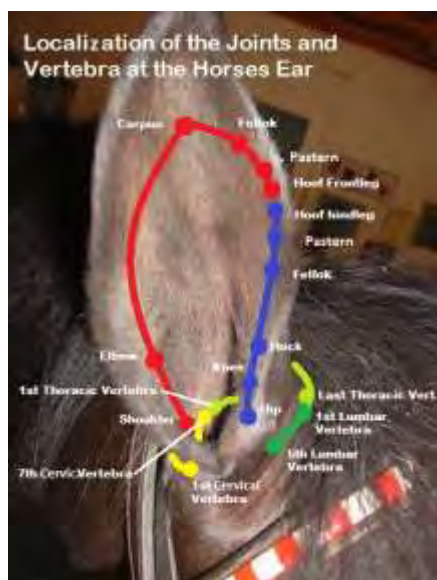

Figure 5: Skeletal structures identified by the author and an auricular map of these created in 2006 (Reprinted with permission from Petermann U. Pulse Controlled Laser Acupuncture Concept (PCLAC). 2007: www.akupunkturtierarzt.de)

acupuncture points without switching for and back between body- and ear- acupuncture. E.g. in a case of a lung infection we can treat the lung point at the ear and we combine it, according to the Middy-Midnight rule (traditional acupuncture rule), with the two “anti-infective” Luo points SP 4 (which is the Interferon-point) and TH 5 (which is the Thymus-point) on the ear.

Still much more interesting seems to me the aspect that, because knowing the locations of all meridian points at the ear, the traditional and modern concept directly can be compared. Almost naturally it showed itself as a complete balanced coverage of TCVM with western medicine. So, when we transposed the Lung meridian to the ear we found the point Lu 7 in the same place, as the ear point (the organ point) of the lung. The same happened when transferring the other meridians. The Kidneys point is identical to the point KID 7, the Liver point to LIV 8, the Stomach point to ST 41, the Uterus point to SP 6, are just a few examples. This is not surprising; finally modern medicine and TCM describe the same facts only from different angles and with different cultural background. Nowhere else as in this aspect of ear acupuncture is so clearly to see, how well TCVM and modern medicine are in harmony with each other. That shall not mean that we copy the mistakes that nowadays very often happen in western medicine like treating only the symptom, not the whole patient!

Twenty-two years ago I started to develop ear maps with the orthopedic localizations and the organ points, first for horses, later for dogs. Finally 2006 for my ear acupuncture book I could finish even the maps for the entire meridian system at the ear in

The system is very reliable and in some cases, even more sensitive than clinical diagnostics, laboratory diagnostics and diagnostic with the help from image giving procedures.

So we can uncover and treat disturbances in a preventative way already before clinical manifestations achieves. The combination with clinical diagnostics to mutual verification and supplementation has been extremely well-proven. With the finding of active points at the ear, I have beside diagnosis also very important acupuncture points for treatment of these ailments. By needling or by lasering these points I can balance vegetative regulation, and thus set the Qi flow in motion again.

In the meantime, the meridians and all traditional acupuncture points are also transposed from the body to the ear. Thus we have the complete meridian system not only on the body but also on the ear. This has the advantage that we can combine the modern ear- points of the joints or the organ points at the ear in a traditional aspect with all thinkable

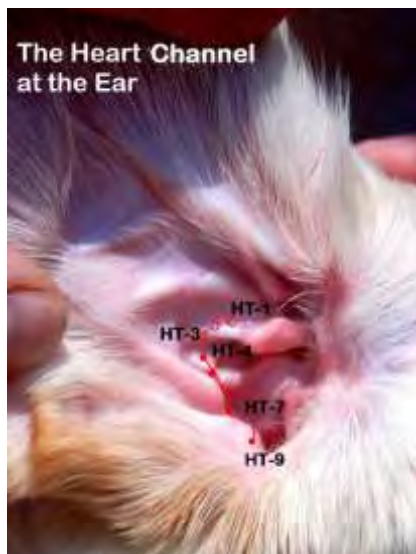

Figure 7: The location of the Heart Channel and Heart acupoints of the ear (Reprinted with permission from Petermann U. Pulse Controlled Laser Acupuncture Concept (PCLAC). 2007: www.akupunkturtierarzt.de)

horses and dogs (figure 7, example pathway of the Herat meridian at the canine ear), another map of psychic points at the ear and some other maps with points with special actions. So now we have almost the whole range of acupuncture diagnostic, as described above available for horses and dogs.

After so-called "Gold Bead Implantation" became more and more important to treat chronic degenerative joint diseases and spondylitis, an interesting application of ear acupuncture is also the implantation of gold beads into the ear points. This is a very simple applied but nevertheless very effective alternative to the conventional method.

A few years ago human ear acupuncture became more recognized also outside Europe, especially in the United States, when Dr. Richard C. Niemtzw from the US Navy took up the idea of ear acupuncture and developed a special very simplified pain acupuncture for the army, called "battlefield acupuncture" where soldiers apply semi-permanent ear

needles to their comrades when hurt in the battlefield. This simplified ear acupuncture is established in the army now and one of the "first aid" treatment concepts.

The third pillar of controlled acupuncture is the so-called RAC-control

The third pillar of controlled acupuncture is the so-called *RAC-control*. *RAC* means "Reflex Auriculo Cardial" and is also attributed to the genius of Dr. Nogier. He watched as he initially by chance felt the pulse of a patient, while he was setting an acupuncture needle, that the sting of the needle spontaneously evocated a marked change in the pulse quality. This again is not the main issue of this lecture but some facts should be mentioned.

Because, as it was his nature, he challenged all things, he found out that this happens quite often, but not in all cases and not always in the same clarity. He could finally see that only points, which also show a strong *therapeutic reaction* in the patients, showed this *strong pulse reaction*. His next step was to find a tool for getting betting provocation results that means stronger RAC reactions to active acupuncture points. Because Dr. Nogier new that acupuncture points have different electric potentials to the surrounding tissue, he tried to provoke the RAC reaction with electric fields of different voltage if he approached to a certain point. He found out that the best result was to achieve with a voltage of 3 Volt. Now he built a diagnostic tool called "3 Volt-hammer".

After this knowledge, he tried to find relationships between known orthopedic disorders and active points at the ear. With help of his observation of the RAC he could

develop an ever more complete map of the joint localizations and even the organ localizations at the ear.

The points of the spine are at the so-called Anthelix in the ear, the limbs are represented at the Scapha and the organ points at the Concha of the ear. From this resulted an image of a curled-up embryo lying in the ear. With help of the RAC one can now search systematically for active, vegetative troubled points using these points for assistance in diagnosis of lameness or diagnosis of inner disorders.

Thus if we find the hip point at the ear as an active point, we know that the hip in its function is disturbed, if we find the point of the 4. Lumbar vertebra, we know that this also is disrupted and very likely is involved of mutual causal link with the hip problem.

Or if we have an active pituitary gland, liver, kidney or pancreas point at the ear we can act on the assumption of a troubled pituitary, liver, kidney or pancreas function. As mentioned, the determined active points are also responsible for treatment.

The RAC diagnosis is not only possible in ear acupuncture but also in the body. A very simple way to get an overview of the pathology of a patient is to make a segmental RAC check, passing along the spine with the 3 Volt hammer and looking for active Shu points.

These have importance in orthopedic disease as vertebra points in connection with back pain but importance as well in internal medicine in connection with the segmental assigned organs. Here we see another holistic aspect of acupuncture. Each orthopedic disease also has an influence on the inner organs and vice versa.

In acupuncture we consider both of these connections automatically.

But even though I intend to operate with quite traditional aspects of acupuncture, I can prove my concept with the RAC check and check out whether the selected points are effective or not. Finally RAC helps us to locate the acupuncture point very simply and exactly. This makes many discussions about point locations unnecessary, because one has to stick the needle there, where the body shows the strong RAC reaction.

The fourth pillar is local laser therapy.

As the fourth pillar, will be amended local laser therapy. Originally, this therapy has nothing to do with acupuncture but it has proved that these two therapies support each other excellently. It is important to stress out that laser acupuncture not only means the stimulation of acupuncture points by the laser beam instead of the needle, but that the application of local laser light is added as an essential component of curative effects to acupuncture treatment, or vice versa, acupuncture as a vegetative therapy supports the local regulatory impact of the laser. Acupuncture and Local Laser Therapy, also called *Low Level Laser Therapy (LLLT)*, are two therapies of same value, each for its own very

effective, but only in its combination in laser acupuncture came together to this holistic approach.

It was once again Dr. Nogier who discovered the capabilities of the laser for acupuncture and again it was the RAC that helped him to optimize the use of lasers in therapy and for acupuncture point stimulation. After *Mester*, the pioneer of medical laser therapy could demonstrate already 1969 the effect of the laser light to support wound healing, Nogier came to the idea that laser, basing on its way it works in tissue, could be useful to stimulate acupuncture points. The first results were successful but not comparable with needle stimulation. His next idea was that the stimulation of acupuncture points (and even tissue) could not only depend on the wavelength of laser light, e.g. blue or red light, as well as different wavelengths in the infrared spectrum. This is of importance for the absorption of laser light in tissues and thus for the effect, but also the frequency of the light pulses at pulsed lasers or a frequency which is modulated on the continuous basic beam at continuously emitting lasers (where the power of the laser beam will alter in the modulated frequency in the form a sine wave).

He experimented with is continually changing frequencies and watched with help of the RAC, in which frequencies the strongest reactions had been to achieve. He developed a row of frequencies, called *Nogier-frequencies* that also in clinical experiment could be proven as very efficient later on.

These frequencies were characterized by special resonance to certain tissues but also to certain tissue conditions. The frequency A is particularly useful for treating inflammation, frequency B has special affinity to ligaments and tendons, frequency C to the bones and joints, the frequency E is stimulating function on the nervous tissue and the frequency F and G on the lower or higher areas of the brain. With these resonance frequencies the point stimulation was much stronger now. A little advantage comparing to needle acupuncture is the short stimulation time of only 20 sec and painless or even contactless point stimulation which makes sense e.g. in treatment of LIV8 (the organ-point of the liver) in a nervous stallion.

Some years later was found another very important row of frequencies from *Bahr* also by the help of the RAC. These *Bahr-frequencies*, which mainly led to the present possibility of a very differential diagnosis in acupuncture, are also very effective therapeutic frequencies. With these Bahr-frequencies one can find out e.g. what is the most important point for treatment. The so called “deep point” – you only find **one** in a patient – is that point where illness started. One example: in most cases of lameness we don’t find the ISJ or the elbow or the Spavin as the deep point, but a special vertebra that influenced the joint to develop chronic lameness. Or another example: in all cases of RAO in horses we don’t find the Lung as the deep point but the Kidneys etc. Another important issue of the *Bahr frequencies* is finding and treatment of *psychic points* in a patient. But most important is fr. 7 according to Bahr, which is a special frequency for finding and treatment of disturbing foci in the teeth. In many cases even in chronic disease one sees symptoms disappear at once after treating the related tooth with laser fr.

7. As the last row of frequencies I will mention here, still relatively new, are “Meridian frequencies” according to *Reininger*.

Reininger could also find with help of the RAC-diagnostic resonant frequencies to all the known meridians, which are in the meantime also proved as important therapeutic frequencies not only to stimulate the respective Meridian points in the sense of acupuncture but also for local tissue therapies, for example, treating the liver with the frequency of the Liver meridians, of the stomach with the frequency of the Stomach meridian, etc. (table 1).

Table 1: Comparison indications and attributes of the Nogier, Bahr and Reininger frequencies used for low-level impulse laser therapy

Nogier Frequencies												
Frequency	A	B	C	D	E	F	G					
Hz	292	584	1,168	2,336	4,672	73	146					
Indications	Wounds, inflammation, irritable foci in body and teeth	Tendonitis, arthritis, fractures, organ acupoints	Tendonitis, arthritis, fractures, all body acupoints except feet	Acupoints of the feet	Nerve and spinal cord diseases	Mandibular joint and subcortical brain disorders	Cerebral cortex and mental disorders					
Bahr 1 Frequencies												
Frequency	1	2	3	4	5	6	7					
Hz	599.5	1,199	2,398	4,796	9,592	19,184	38,368					
Indications and Attributes	Deep tissue layer, “deep” points (source of illness)	Central tissue layer, hormonal and nervous system	Surface tissue structures, Omega <i>Ren</i> Channel	Omega <i>Du</i> Channel	Opening acupoints of the Eight Extraordinary Channels	Governing Vessel	Conception Vessel, abnormal foci in teeth					
Reininger Frequencies*												
Channel	LIV	ST	HT	PC	LI	GB	KID	BL	SP	TH	SI	LU
Hz	442	471	497	530	553	583	611	667	702	732	791	834

*Used for treatment of acupoints on specific Channels and topical treatment of related organs; LIV=Liver, ST=Stomach, HT=Heart, PC=Pericardium, LI=Large Intestine, GB=Gallbladder, KID=Kidney, BL=Bladder, SP=Spleen, TH=Triple Heater, SI=Small Intestine, LU=Lung Channels

Indications in Dogs and Horses

Where can laser acupuncture be helpful?

- Acute bronchitis
- Chronic bronchitis
- Pneumonia
- Liver disease

- Kidney disease
- Heart disease
- Ovary disease
- Incontinentia
- Acute and chronic lameness
- Discopathia
- Strain
- Contusion
- Arthrosis
- Laminitis
- Back problems incl. “Kissing Spines”
- Hip dysplasia
- Elbow dysplasia OCD
- Paralysis
- Teeth cysts
- Sinusitis
- Eye injuries
- Wound healing
- postoperative wound healing
- postoperative convalescence
- Abscess maturation

...and many others

Even if I basically will not miss local laser therapy in any treatment any more, there are some examples where local laser therapy is of a very special importance. This is the therapy of infected joints and tendon sheaths, tissue infection especially with multi resistant germs including MRSA-infections, in wound healing, especially with wound healing disturbances, tendonitis of the horse, nerve lesions and paralysis.

By means of some examples I will demonstrate the options of laser acupuncture.

Case Examples

The following case examples illustrate the application of PCLAC; pulse controlled (guided) laser acupuncture. First the auricular points are checked (scanned) with the laser to quickly evaluate the whole body for “active” points. Next the corresponding body acupoints and in some cases the teeth are scanned with the laser devices on specific diagnostic frequency settings. Next the treatment strategy and acupoint selection are made based on the pulse changes and knowledge of basic TCVM. Finally all “active” acupoints on the ear, body and limbs as well as acupoints with special effects and in some cases the auricular points are treated with LLLT using a Physiolaser Olympic device at the optimum frequency for the acupoint, Channel, organ or dysfunction. All acupoints are treated for 20-30 seconds. Local tissues on the body or organs are usually treated with the Physiolaser Olympic LLLT unit using the cluster probe (large areas) or single probes (teeth) for 1-5 minutes.

Case example 1

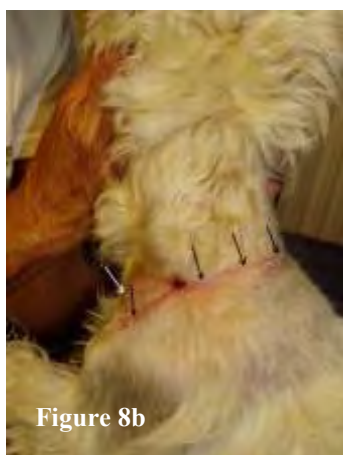

Figure 8b

A six year old male Scotch terrier was bitten by a male Doberman. Three-quarters of the skin circumference around the neck was lacerated. Picture 1 shows the dog one week after the wound was stitched in a veterinary clinic. In spite of wound drainage and giving antibiotics to the dog one sees that a complete wound dehiscence starts to occur (Figure 8a, see the black gangrenous tissue marked by a white arrow). Two days later the dog came to me with a complete dehiscence

and the wound was as big as the size of the whole hand. Over the course of 12 days four laser acupuncture treatments were needed to close the wound completely (Figure 8b, see the thin scar along the black arrows) without any other surgery and without any further antibiotics or other drugs. For each treatment we did LLLT of the wound with 5x 30 Watt laser shower for ten minutes and TH 5 for wound demarcation, SP 4 for treating wound infection and SP 2 for wound repair were treated with 90 Watt pulse laser for 30 sec each, nothing else!



Figure 8a

Figure 8a and 8b, Necrotic wound before dehiscence (see arrow) and 12 days later complete healing without surgery and antibiotics (arrows). (Reprinted with permission from Petermann U. Pulse Controlled Laser Acupuncture Concept (PCLAC). 2007: www.akupunkturtierarzt.de)

Case example 2

MRSA infection in a dog

The case of an MRSA infection in a dog shows the excellent anti-infective effect of Laser Acupuncture even in such cases, in which antibiotics have no effect. You can go as far as here that Laser Acupuncture is currently the only successful treatment possibility.

A three year-old German shepherd mix was presented for Laser Acupuncture after a four months permanent treatment in a small animal hospital. It had been completely unsuccessful and had been stopped. Euthanasia of the dog was recommended to the owner, because there was finally no way to help. But the owner asked me whether Laser Acupuncture would be able to cure MRSA infection. I answered truthfully that I didn't treat MRSA infections before, but many other antibiotics resistant infections have successfully been treated.

The dog was introduced to the pre-treating veterinary hospital because of a small wound unclear in origin. The wound was cleaned and antibiotically supplied. Despite the therapy, the wound swelling gained rapidly, showed suppurative fistulation and pain. It

was then taken a tissue sample from the infected area investigated. A MRSA infection could be verified.

The clinic tried a further therapy with selected combinations of antibiotics that were diversified several times. But this also showed no improvement. Swelling, fistulation and pain gained further on. As a last resort was considered, a wide-scale excision of the diseased tissue which was carried out very carefully. But the wound, already after a few days, showed a dehiscence with massive infection. The clinic advised to euthanasia of the dog, as the infection and pain got too strong and was no more manageable. There was no chance of healing any more.

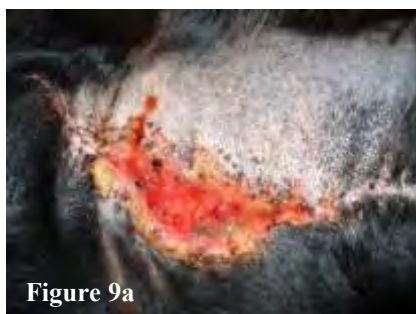

Figure 9a

At that state the dog came to me. The wound showed a highly destructive infiltrative infection. The granulation tissue was tubercular and awesome secreting (figure 9a). At the beginning of the Laser Acupuncture medical therapy (antibiotics and anti-inflammatory drugs) was spontaneously discontinued.

In addition to LLLT of the wound with the frequency A' for 10 minutes the immune stimulating points TH 5 (Thymus point) and SP 4 (Interferon inducing point) were treated. Already during the first session the wound showed a typical spontaneous superficial secretion and a spontaneous reduction in pain could be observed. After 10 days (5 treatments) a significant contraction with beautiful epithelization and clean granulation tissue was to see (figure 9b). One month after the start of Laser Acupuncture the wound had healed without a visible scar (figure 9c).

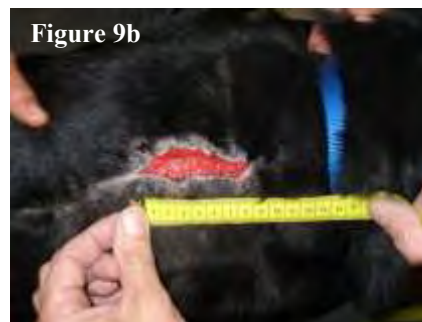

Figure 9b

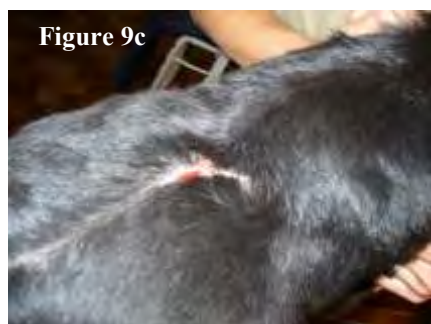

Figure 9c

Figure 9a, MRSA infected wound before laser acupuncture. **Figure 9b**, 10 days later. **Figure 9c**, complete healing without further surgery and antibiotics
Petermann 2011, (Reprinted with permission from: Kontrollierte Laserakupunktur, Sonntag Verlag in MVS Medizinverlag. Stuttgart, Germany: Thieme Verlagsgruppe 2011)

Case example 3

A four year old male German Shepherd Dog with extreme pyodermia from its birth was treated for its whole life with conventional medicine without success. This is an example how a disturbing focus in the navel was caused by Mercury pollution the dog got from its mother. This was responsible for an atopic dermatitis from its birth on. The dog was itching all day long and had significant loss of weight. The dog was extremely

nervous. One could see its ailments on its skin. The area of Lung, Liver, Kidney and Large Intestine showed loss of hair and inflammation.

Following treatment was applied once a week: LLLT of the disturbing focus navel with Fr.A, TH 5, KID 3 (Fr. 5), KID 7, LIV 8, LU7, LI 11 (Fr. B). The treatment was carried out once a week. Figure 11 shows the same dog 8 weeks later: 15 kg increase of weight with full hair, no itching, calm and healthy the first time in its life.

Case example 4

A two year-old crossbred stallion with a tarsal joint infection

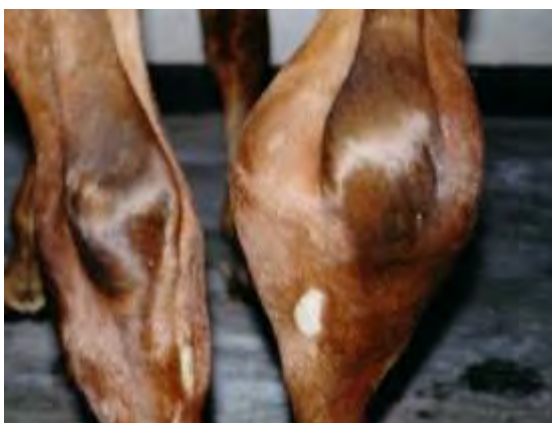

Figure 10a: A right tarsal joint infection of 6 months duration in a two-year-old crossbred stallion. On presentation the hock circumference was 61cm.

healthy tarsal joint was 42 cm (Figure 10a). The horse could not put weight on the affected limb and hobbled along on three legs with great effort. This first example will be described more in detail.

PCLAC diagnosis and treatment

First the auricular points were scanned for an RAC (VAS) using Bfr-1 (599.5 Hz), the best frequency to detect “deep” points. The auricular point for the hock was “active” and determined to be the “deep” point (Figure 3). Therefore the hock appeared to still be the primary area affected and treatment of that region was performed first. Topical LLLT, using a 5 x 30 Watt impulse laser with the Physiolaser Olympic cluster probe was applied to the dorsal, medial and lateral surfaces of the hock joint for 5 minutes each, using Nfr-A (292 Hz) known to reduce inflammation.

An RAC (VAS) scan of local tissues was also performed using Nfr-A (292 Hz, for inflammation) and a strong reaction was found at the tracts where the endoscope was inserted.

These areas were treated with Nfr-A (292 Hz) with a 90 Watt LLLT single probe for 1 minute each.

The Tendinomuscular Meridians (TMM or Sinew Channels) are a system of superficial Channels that control the tendons, muscles and skin and are related to the regular Channels. The TMM of the Liver and Gallbladder Channels that passed by the joint infection were treated with Rfr-LIV (442 Hz) and Rfr-GB (583 Hz).

Then acupuncture points on the body were tested for an RAC (VAS) reaction with the positive pole (red side) of the 3-volt hammer and with the LLLT device on the diagnostic setting at specific frequencies to detect Deficiencies and LIV-1, LIV-8, GB-44, GB-43, SI-18 and CV-3 were “active” acupoints.

LIV-1 (Ting point) and LIV-8 (Liver tonification point) were treated with Rfr-LIV (442 Hz) for 20-30 seconds.

GB-44 (Ting point) and GB-43 (tonification point) were treated with Rfr-GB (583 Hz) for 20-30 seconds.

SI-18 (Reunion point of the Yang TMM of the foot) with Rfr-SI (791 Hz) for 20-30 seconds.

CV-3 (Reunion point of the Yin-TMM of the foot) was treated with Bfr-7 (38,368 Hz) for 20-30 seconds.

The Cardinal (Opening) points of the Eight Extraordinary Channels (LU-7, KID-6, SP-4, PC-6, SI-3, BL-62, GB-41 and TH-5) were tested for a RAC (VAS) with Bfr-5 (9,592 Hz) useful for detecting “active” Opening points.

GB-41 and TH-5 were detected as “active” Opening points and were treated for 30 sec with a 90-Watt impulse laser.

Back Shu Association points were tested with the positive pole of the 3-volt Hammer to detect Deficiencies.

BL-18 and BL-23 were found to be “active” and were treated with Nfr-C (1,168 Hz) for 30 seconds.

The same treatment was given seven times over a 2-week period and the circumference of the joint reduced to 47 cm and the horse walked without lameness (Figure 10b). After 5 minutes of trotting, he could also trot without lameness. He was

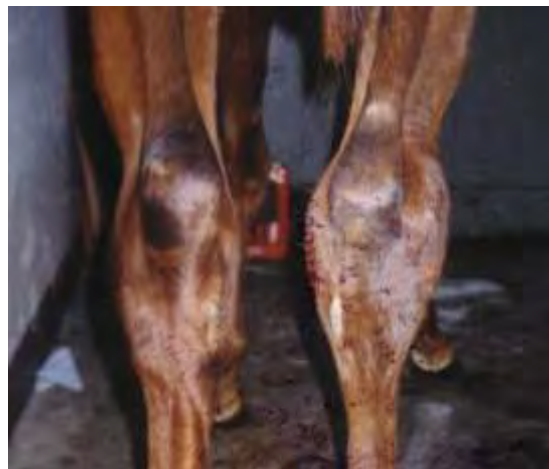

Figure 10b: The right tarsal joint infection of 6 months duration in a two-year-old crossbred stallion; After seven LLLT treatments over a 14 day period, the circumference had reduced to 47cm. (Reprinted with permission from: Petermann U. Kontrollierte Laserakupunktur

doing so well that the client began exercising him, but within 3 days of beginning the exercise program, inflammation of the joint re-appeared and the body temperature increased to 41°C (105.8°F). The horse was not treated with antibiotics or any other drugs. Again only local LLLT and pulse controlled laser acupuncture were used as before, but treatment of SP-4 (Interferon point) with Reininger fr-SP (702 Hz) was added to the next four treatments to further reduce the inflammation. After approximately one month and twelve additional treatments, the patient had recovered. Over the following three months, training was gradually increased to full capacity. The horse was then sold six months later as a competition horse and passed purchase inspection by a veterinarian.

Case Example 5



Figure 11a: A 13-year-old Arabian mare that had suffered from recurrent airway obstruction (RAO) for the past 9 years duration. On presentation the horse had severe respiratory distress with flared nostrils and an expression of panic in her eyes. Her respiration rate was 56 breaths/minute.

A 13 year-old Arabian mare with recurrent airway obstruction (RAO) for nine years.

The mare's RAO had become so severe in the past few years that the client and referring veterinarian were considering euthanasia. As a last resort the horse was referred to the author for acupuncture. On the initial examination, the respiration rate was 56 breaths/minute and the horse had extreme abdominal contraction on expiration. The horse had respiratory distress and the nostrils were severely flared and his panic showed in his eyes (Figure 11a). Loud wheezing respiratory sounds could be heard, 20 meters away from the patient. The lung percussion field had dilated to about two hands width and loud percussion sounds

could be heard in this area. Bronchoscopy could not be performed because of the critical condition of the horse. Only after the second LLLT acupuncture treatment was the horse's condition stable enough for bronchoscopy. On bronchoscopy there were cobweb-like threads of high viscosity mucous inside the trachea and the stem bronchi. The mucous membranes were very reddened especially at the bifurcation of the trachea. The stem bronchi sometimes would collapse during expiration. Since abnormal foci in the teeth are often responsible for hyperactivity of the immune system and RAO, the teeth were tested for an RAC (VAS) with the laser Bfr-7 (38,368 Hz), the optimum frequency to evaluate abnormal teeth foci. The 2nd molar of the upper jaw on each side induced an RAC (VAS) and so were treated with topical LLLT at the same frequency (Bfr-7) for 3 minutes with the Physiolaser 90w/904nm LLLT single unit. An RAC (VAS) was found at the following auricular points using the Bahr frequencies as indicated and were treated with the same frequencies: the auricular Kidney point (KID-7) diagnosed and treated with Bfr-1 (599.5 Hz) for 20-30 seconds. The auricular Lung point (LU-7) was diagnosed and treated with Bfr-2 (1,199 Hz) for 20-30 seconds.

The auricular β -receptor point (ST-40) was diagnosed as Deficient with Rfr-ST (471 Hz) and ST-40 on the pelvic limbs was treated for 20-30 seconds with the same frequency, the auricular Yuan Source point for Kidney (KID-3) was diagnosed as Deficient using Bfr-5 (9,592 Hz) and KID-3 on the pelvic limbs was treated for 20-30 seconds with the same frequency, the auricular Thymus point (Opening point for the Yang Wei Channel) was diagnosed as Deficient with Bfr-5 (9,592 Hz) and TH-5 on the thoracic limbs was treated for 20-30 seconds with the same frequency.



Figure 11c: The same 13-year-old Arabian mare in Figures 11a and 11b shown galloping across the field and feeling great one month after completing seven LLLT treatments every 3-4 days. The horse continues to do well 2 years later. (All reprinted with permission from: Petermann U. Kontrollierte Laserakupunktur bei Hund und Pferd. Sonntag Verlag in MVS Medizinverlag. Stuttgart, Germany: Thieme Verlagsgruppe 2011)



Figure 11b: The same 13-year-old Arabian mare in Figure 8a after 40 minutes of LLLT acupuncture treatment. Her breathing had improved and the rate had decreased to 28 breaths/minute. She was no longer panicked and her nostrils were not flared

During the treatment of the teeth with topical LLLT, the horse sighed and breathing began to improve. By the end of the complete LLLT treatment, the respiration rate had decreased by 50% to 28 breaths/minute, the panic was gone and the nostrils were no longer flared (Figure 11b). Seven similar treatments were given every three to four days. A month after the seventh treatment, the horse was clinically normal and capable of galloping across the fields without any problem (Figure 11c). Bronchoscopy was repeated and no abnormalities were observed in the airways. The lung field detected by lung percussion had returned to normal. The horse has remained healthy now for approximately two years and according to the caretaker has been healthier than she had ever been.

Even if this shows only a small number of many comparable cases I saw in the last 25 years and a small insight into the complete concept of Pulse Controlled Laser Acupuncture I hope to wake up some interest for this wonderful modern holistic treatment concept.

I believe we should save and cherish all ancient knowledge in acupuncture, but that cannot mean that there shall not be an improvement. Times, life, diseases, environment and technique has changed in the last 3000 years since Sunjang the father of

veterinary acupuncture already treated horses successfully with acupuncture. We should keep the tradition but shouldn't ignore modern concepts in acupuncture.